

Morphometric Evaluation of Adult Acromion Process in North Indian Population

SUSMITA SAHA¹, NEELAM VASUDEVA²

ABSTRACT

Introduction: Dimensions of acromion process are important to show linkage to the shoulder girdle pathologies. Also morphometric analysis of acromion process would be helpful for surgeons while performing surgical procedures on the shoulder joint.

Aim: The purpose of this present study was to observe the detailed morphometric evaluation of adult acromion processes in North Indian population because different morphometric dimensions play an important role in various disorders of the shoulder, particularly sub acromial impingement syndrome.

Materials and Methods: Two hundred adult dry scapulae from the osteology museum of MAMC, New Delhi, were obtained for evaluation of various measurement of acromion process. The length, width, thickness of acromion, coraco-acromial (C-A)

distance and acromio-glenoid (Ac-g) distance were measured. The measurements were compared with other osteological studies performed on different population group. Data was analysed using SPSS version 12.0 and mean values with standard deviation for each dimension were presented.

Results: The mean values of each measurement were: length: 41.007 mm; width: 21.82 mm; thickness: 6.58 mm; C-A distance: 28.34 mm and Ac-g distance: 26.21 mm.

Conclusion: It is expected that various dimensions of adult acromion process will serve as a reference base and will assist the surgeon in the approach to be used and precision of the operative technique. So, the study will provide a vital support for planning and executing acromioplasty in the treatment of impingement syndrome.

Keywords: Acromioplasty, Morphometry, Scapula, Subacromial impingement syndrome

INTRODUCTION

The acromion process projects forward almost at right angles, from the lateral end of the spine of the scapula. It is one of the components of the coracoacromial arch which forms the superior boundary of the subacromial space [1]. The Coraco acromial ligament spans between tip of the acromion and coracoid process thus it forms coraco-acromial arch [1]. The space below the arch gives passage to the tendons of muscles forming musculorotator cuff. Any abnormality that disturbs the relationship of the subacromial structures may lead to impingement syndrome [2,3]. Surgical procedures such as acromioplasty or acromionectomy are used for the treatment of impingement syndrome [2]. Morphological variations of the acromion process & its relationship with the glenoid cavity & coracoid process is the most relevant factor determining the height of subacromial space [4]. Any variations of these structures can predispose the pathogenesis of the impingement syndrome. The concept of Subacromial Impingement Syndrome (SAIS) was introduced by Neer in 1972 and represents mechanical compression of the rotator cuff, subacromial bursa, and biceps tendon against the undersurface of the acromion and coracoacromial ligament, especially during elevation of the arm [2,5]. They also focused on the cause and effect relationship between acromial morphology and SAIS and proposed that variations in the shape and slope of the anterior aspect of the acromion were responsible for SAIS and associated tears. In 1909, Goldthwait described differences in the shape and slope of the acromion [6]. In 1986, Bigliani et al., identified three types of acromial morphology: flat; curved and hooked and this morphological classification has been the dominant diagnostic tool for the impingement syndrome and rotator cuff tears [7] and they also noted an increase in rotator cuff tears with type - III or hooked acromion. Another study in 2007, Natsis et al., [8] conducted a cadaveric study by visual inspection on 423 dried scapulae & demonstrated a fourth type of acromion process which

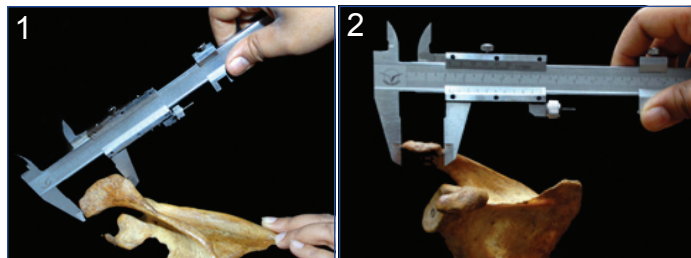
was only 2.6% along with the three types of acromion process as described by Bigliani et al. In 2011, Type II acromion process was predominantly noticed in Indian population in accordance with Getz morphometric classification of acromion process [9,10]. Other investigators have also suggested that variations in the acromial morphology have a great role in the pathogenesis of rotator cuff tears [11-13]. Edelson and Taitz concluded that the slope and length of the acromion and the height of the arch were most closely associated with degenerative changes. Not only the length, but also considerable variations are seen in the thickness and width of the acromion [14]. It helps anthropologists during their study on evolution of acromion process. Though acromion process plays important role in the formation, stability and surgical interventions to the shoulder joint so, various dimensions of acromion process are also important factors which can be taken into consideration for acromioplasty, a surgical procedure used for treatment of rotator cuff impingement syndrome [2,5]. In one of the study performed by Singh J et al., on 129 dried scapulae have also reported about acromial morphometry among Indian population [15]. So, there is a shortage of reports on literature about different morphometric parameters of acromion processes in Indian population. Thus, the present study was conducted on a large number of acromion processes in dry scapulae which is expected to serve as a reference base in North Indian population. Considering the increasing number of such cases, it is also expected to facilitate the surgeons in the management of such patients.

MATERIALS AND METHODS

In this observational study, morphometric evaluation of acromion processes were done on 200 adult dry scapulae obtained from the osteology museum of Anatomy department, MAMC, New Delhi over a period of one & half year. All scapulae were inspected and generalized anatomic descriptions were recorded. All measurements


were done with the help of Vernier Caliper (manual version). Measurements were taken twice and then average was taken to reduce the bias errors.

The following acromial parameters were studied: length measured along the middle of the acromion, from the tip of the acromion process up to the acromial angle (A-P length); width was measured across the middle of the acromion from the lateral aspect to the acromion to its medial side (M-L length); Thickness (Th 1, 2, 3) was measured along the lateral edge at three different points- one at the anterior end of acromion, second at the middle of the acromion and third near the posterior end of the acromion process. Finally, the average of these three measurements was taken as thickness of the acromion process. Apart from all these three measurements, distance of the acromion process from the coracoid (C-A dis) and superior rim of the glenoid (supraglenoid tubercle) were measured



[Table/Fig-1]: Length of acromion process.

[Table/Fig-2]: Width of acromion process.



[Table/Fig-3]: Thickness at anterior most end of acromion process.;

[Table/Fig-4]: Measurement of Coraco-acromial distance.



[Table/Fig-5]: Distance between supraglenoid tubercle to acromion process.

as coraco acromial length and acromio glenoid distance (Ac – g dis) as shown in [Table/Fig-1-5].

STATISTICAL ANALYSIS

Data was analysed using SPSS version 12.0 and mean values with standard deviation for each dimension were presented in [Table/Fig-6].

RESULTS

In this present observational study, 200 dry scapulae were evaluated for various morphometric parameters of the acromion process. Among 200 scapulae 91 were of right side and 109 of left side. Measurements were taken in all 200 scapulae randomly, not according to the side. The mean value for acromial length was 41.007 mm in total sample; Acromial width was 21.82 mm; coraco acromial distance was 28.43 mm; Acromio glenoid distance 26.21mm and Thickness 6.58 mm. The minimum, maximum, mean

Parameters	N	Minimum	Maximum	Mean	Std. Deviation
Length	200	21.58	59.72	41.0079	6.6462
Width	200	14.42	35.82	21.8288	2.93429
Coracoacromial Distance	200	18.92	70.52	28.4326	5.30824
Acromio glenoid distance	200	19.36	35.94	26.2145	3.33932
Thickness	200	3.91	9.58	6.5888	1.28324

[Table/Fig-6]: Descriptive statistics of all the parameters (in mm).

and standard deviation of the above parameters is shown in [Table/Fig-6]. Though the results are of descriptive statistics type, so test for significance has not been applied.

DISCUSSION

Impingement of the rotator cuff beneath the coracoacromial arch has been recognized as one of the cause for chronic disability of the shoulder. The disappointing results of complete acromionectomy and lateral acromionectomy stimulated investigators to probe the undersurface of acromion in the genesis of the impingement syndrome [2,5]. It has been noticed that lateral acromionectomy is having unsatisfactory results with lots of complications [2]. Because of this major issue, removal of anterior edge & the undersurface of anterior most part of acromion process along with coracoacromial ligament was recommended which is named as anterior acromioplasty [2,5]. An acromioplasty is a surgical technique to shave the undersurface of the acromion so that it gets flattened. The prerequisite for doing this surgical procedure with precision is to know the different morphometric parameters of acromion as well as its distance from the coracoid process and the supraglenoid tubercle [4]. In our study we have performed various morphometric parameters of the 200 adult acromion processes and the mean value of each measurement were measured. Edelson JG et al., performed various measurements of adult scapula among Israel population and concluded that the slope and length of the acromion, the height of the arch are most closely associated with degenerated changes [14]. Nicholson et al., in their cadaveric study of scapulae in the American population documented fundamental qualitative difference in the size of the acromion both in males and females [11]. The average acromial dimensions noticed were: in females; length 40.6 mm, width 18.4 mm and thickness 6.7 mm. In males; length 48.5 mm, width 19.5 mm and thickness 7.7 mm which were subjected to multiple regression analysis and no significant change in the dimensions was noted within each sex. According to Anetzberger and Putz acromial length was 47.00 mm [16]. Von Schroeder studied acromial morphometry among German population in both sexes and noted that in males: length was 50.9 mm, width 22.9 mm, thickness 9.8 mm C-A dis 28.7 mm and AC- g dis 16.1 mm. In females: the length was 43.6 mm, width 20.4 mm, thickness was 8.7 mm, C-A dis 24.6 mm and Ac-g dis was 14.9 mm [17]. Sitha et al., noticed acromial length 40.0 mm, width 23.0 mm among Thais population [18]. Similar studies among Turkish population conducted by Coskun et al., had reported the length 44.7 mm and width 32.0 mm [19]. In 2007, Torres et al., evaluated

scapulae in the Brazilian population and observed the acromial length 49.6 mm, C-A dis 38.5 mm, Thickness 7.2 mm and Ac –g dis 29.5 mm [4]. Study done by Paraskevas et al., among Greek population mentioned acromial length 46.1 mm, width 22.3 mm, C-A dis 28.1 mm, thickness 8.8 mm and Ac-g was 17.7 mm [11]. In another study Mallon et al., took the measurements from radiographs and recorded the acromion length of 42.0 mm [20]. Mansur et al., studied 68 scapulae among Nepalese population and observed average acromial length as 46.6 mm in right scapula, 45.57 mm in left side [21]. They have also found that width of right scapula was 26.63 mm and left scapula 27.73 mm; acromio glenoid distance on right side was 31.38 mm and 31.97 mm on left side. But their study showed that there was no statistical differences between right and left side ($p= 0.398$). In 2013, Singh J et al. observed acromial length, width, thickness, coracoacromial distance among 129 dry scapulae according to right & left side among Indian population and documented the total mean as 46.1 mm, 23.2 mm, 6.60 mm and 37.5 mm respectively [15]. They have also not mentioned any statistical differences among the sides of the scapulae. In the present study among 200 dry scapulae, we have observed the acromial length, width, thickness, coracoacromial distance and acromio glenoid distance as 41.09 mm, 21.8 mm, 6.5 mm, 28.4 mm and 26.6 mm respectively. So, our results are almost similar to the studies on German; Thais and American population. But, our results are less than the result of Singh J et al., among the same population group. Apart from length; width; thickness & coracoacromial distance, we have also measured acromio glenoid distance (Ac-g) [Table/Fig-7] [4,11,12,15,17-19,21]. These dimensions of acromion process hold clinical important as well as anthropological values, so recently we have conducted this morphometric evaluation is conducted on a larger sample size among Indian population.

It is noticed that, many authors have studied acromial morphology and morphometry in different population group with different sample sizes. But, to the best of our knowledge, very few studies have undertaken the evaluation of acromial morphometry in Indian population. Knowing the data on the shape and various distances of acromion may help the orthopaedicians during surgical repair around the shoulder joint. It may also be of interest to the anthropologists when studying about the evolution of the erect posture and bipedal gait. The morphometric analysis of the acromion should be used like an auxiliary mean to promote a better knowledge about the disease that appears in this area. Moreover, distances from palpable bony landmarks provide useful information for placement of ports in the arthroscopic intervention of the shoulder joint.

LIMITATION

We have taken measurements among dry bones only; radiographic measurements can also be performed later. Moreover, we have performed the study on dry bones randomly irrespective of the sexes whether males or females. Gender-specific differences among the dimensions have not been studied in the present study; so, measurements can be studied in a large number of sample sizes according to the sex also.

CONCLUSION

Morphometric parameters are vital for planning and executing acromioplasty. Though there is a shortage of literature about morphometric evaluation of acromion process in Indian population, these morphometric data will serve as a reference base for the clinicians. Also, if the initial thickness of acromion is available, then it goes a long way in helping the orthopaedic surgeons to decide how much bone needs to be swan and how much can be saved to maintain the rotator cuff dynamics post surgery. The measurements of other parameters assist the surgeon in the approach to be used and precision of the operative technique.

REFERENCES

- [1] Ellis H, Johnson D. Pectoral girdle and upper limb. Gray's Anatomy. 39th ed. 2004;817-49.
- [2] Neer CS. Impingement lesions. Clinical Orthopedic Related Researches. 1983;173:70-77.
- [3] Meyer AW. The minuter anatomy of attrition lesions. J Bone Joint Surg. 1931;13:341-60.
- [4] Torres CA, Riberio CS, Maux SXDA, Oliveria GCD, Neves MG, Salgado ARF, et al. Morphometry of acromion process and its clinical importance. Int J Morphol. 2007;25(1):51-54.
- [5] Neer CS. Anterior acromioplasty for the chronic impingement syndrome of the shoulder. J Bone Joint Surg Am. 1972;54:41-50.
- [6] Goldthwait JE. An anatomic and mechanical study of the shoulder-joint, explaining many cases of painful shoulder, many of the recurrent dislocations and many of the cases of brachial neuralgias or neuritis. Am J Orthop Surg. 1909;6:579-606.
- [7] Bigliani LU, Morrison DS, April DW. The morphology of acromion and rotator cuff impingement. Orthop Trans. 1986;10:228.
- [8] Natsis K, Tsikaras P, Totlis T, Gigis I, Skandlakis P, Appell HJ, et al. Correlation between the four types of Acromion & the existence of enthesophytes: A study of 423 dried scapulas. Clinical Anatomy. 2007;20:267-72.
- [9] Saha S, Vasudeva N, Paul S, Virendra GK. Study of acromial morphology in Indian population. Rev Arg de Anat Clin. 2011;3(2):83-87.
- [10] Getz JD, Recht MP, Piraino DW, Schlis JP, Latimer BM, Jellema LM, et al. Acromial morphology: Relation to sex, age, symmetry and subacromial enthesophytes. Radiology. 1996;199:737-42.
- [11] Nicholson GP, Goodman DA, Flatow EL, Bigliani LU. The acromion: Morphologic condition and age related changes. A study of 420 scapulas. J Shoulder Elbow Surg. 1996;5:1-11.

References	Population	A-P length (mm)	M-L length (mm)	C-A dis (mm)	Thickness (mm)	Ac-G length (mm)	
Nicholson [11]	American	Male	48.5	19.5		7.7	
		Female	40.6	18.5		6.7	
Von Schwender et al., [17]	German	Male	50.7	22.9	28.7	9.8	16.1
		Female	43.6	20.4	24.6	8.7	14.9
Sitha [18]	Thais	40	23				
Coskun [19]	Turkish	44.7	32				
Torres et al., [4]	Brazilian	49.6		38.5	7.2	29.5	
Paraskevas et al., [12]	Greek	46.1	22.3	28.1	8.8	17.7	
Mansur [21]	Nepalese	46.6	26.63			31.4	
Singh J [15]	Indian	46.1	23.3	37.5	6.6		
Present study 2015	Indian	41.9	21.8	28.4	6.5	26.6	

[Table/Fig-7]: Distribution of the morphometric evaluation of acromion process in different population group [4,11,12,15,17-19,21].

- [12] Paraskevas G, Tzaveas A, Papaziogas B, Kitsoulis P, Natsis K, Spanidou S. Morphological parameters of the acromion. *Folia Morphol.* 2008;67:255-60.
- [13] Ozaki J, Fujimoto S, Nakagawa Y, Masuhara K, Tamai S. Tears of the rotator cuff of the shoulder associated with pathological changes in the acromion. A study in cadavers. *J Bone Joint Surg. Am.* 1988;70:1224-30.
- [14] Edelson JG, Taitz C. Anatomy of coracoacromial arch. Relation to degeneration of the acromion. *J Bone Joint Surg.* 1992;74(B):589-94.
- [15] Singh J, Pahuja K, Aggarwal R. Morphometric parameters of the acromion process in adult human scapulae. *Indian Journal of Basic Applied Medical Research.* 2013;8(2):1165-70.
- [16] Anetzberger H, Putz R. The scapula: principles of construction and stress. *Acta Anat Basel.* 1996;156:70-80.
- [17] Von Schroeder HP, Kuiper SD, Botte MJ. Osseous anatomy of the scapula. *Clinical Orthopaedic and Related Research.* 2001;383:131-39.
- [18] Sitha P, Nopparatn S, Aporn CD. The scapula: Osseous dimensions and gender dimorphism in Thais. *Siriraj Hosp Gaz.* 2004;56(7):356-65.
- [19] Coskun N, Karaali K, Cevikol C, Bahadir M, Demirel BM, Sindel M. Anatomical basics and variations of the scapulae in Turkish adults. *Saudi Med J.* 2006;27(9):1320-25.
- [20] Mallon WJ, Brown HR, Vogler JB, Martinez S. Radiographic and geometric anatomy of the scapula. *Clin Orthop Relat Res.* 1992;277:142-54.
- [21] Mansur DI, Khanal K, Haque MK, Sharma K. Morphometry of acromion process of human scapulae and its clinical importance amongst Nepalese population. *Kathmandu Univ Med J.* 2012;38(2):33-36.

PARTICULARS OF CONTRIBUTORS:

1. Assistant Professor, Department of Anatomy, SGT Medical College, Hospital and Research Institute, Budhera, Gurgaon, India.
2. Director Professor and Head, Department of Anatomy, Maulana Azad Medical College, New Delhi, India.

NAME, ADDRESS, E-MAIL ID OF THE CORRESPONDING AUTHOR:

Dr. Susmita Saha,
Department of Anatomy, SGT Medical College, Hospital and Research Institute, Budhera, Gurgaon – 122505, India.
E-mail: drsusmita.sh@gmail.com

Date of Submission: **May 02, 2016**Date of Peer Review: **Jun 25, 2016**Date of Acceptance: **Sep 25, 2016**Date of Publishing: **Jan 01, 2017****FINANCIAL OR OTHER COMPETING INTERESTS:** None.